



Rajasthan

National Health Mission
(NHM)

Staff Nurse

(Nursing)

Volume - 5

INDEX

S No.	Chapter Title	Page No.
1	OBG	1
2	Miscellaneous	94

1 CHAPTER

OBG

Obstetrics

- Branch of medical science dealing with **pregnancy & related disorders**.

Gynecology

- Branch of medical science dealing with **female reproductive system & disorders (other than pregnancy)**.

Important Names

- **Father of Modern Gynecology** → *James Marion Sims*
- **Indian Father of Gynecology** → *Dr. Balchand Nilkanth Purandare*

Female Reproductive System

Definition: Organs & structures involved in **production, transport & nurturing** of female gametes (ova).

A) External Genitalia (Vulva / Pudendum)

(Developed from **ectoderm**)

1. Mons Pubis (Mons Veneris)

- Hair-bearing **triangular area** above clitoris
- **Most anterior** part of vulva

2. Clitoris

- Small erectile body (length ≈ **2.5 cm**) above urethral opening, below mons pubis
- **Parts:** Crus, Bulb, Body
- **Homologous to:** *Glans penis in male*
- **Function:** Sexual stimulation only (not reproductive)
- Contains **erogenous zone** → “love producing”
- **Surgery Qs:**
 - ✓ *Metoidioplasty* = female → male conversion with HRT
 - ✓ *Phalloplasty* = penis reconstruction

3. Labia Majora

- Outer skin folds (hairy + sebaceous glands)
- **Homologous to:** *Scrotum in male*
- **Embryology:** Develops from labio-scrotal folds

4. Labia Minora

- Inner thin folds (no hair, contain sebaceous glands)
- Form boundary of **vestibule**
- **Homologous to:** *Penile urethra in male*
- Posterior end meets → forms **Fourchette**
- **Clinical Q:** Episiotomy (most common obstetric procedure in India, 2nd degree)

5. Vestibule

- Triangular space bounded by:
 - ✓ Superiorly → Clitoris
 - ✓ Inferiorly → Fourchette
 - ✓ Laterally → Labia minora

➤ **Openings present:**

- ✓ **Urethral opening** → below clitoris, above vagina
 - Female urethra = **4 cm (short)** → ↑ risk of UTI (*E. coli*)
- ✓ **Vaginal opening (introitus)** → below urethra, above fourchette
 - Surrounded by **Hymen** at birth
 - Hymen can rupture due to intercourse, cycling, exercise, horse-riding
 - Remnants = **Carunculae myrtiformes**

6. Bartholin's Glands

- 2 glands → situated below vaginal opening (posterolateral vestibule)
- **Type:** Exocrine gland
- **Function:** Secrete alkaline mucus during intercourse
- **Homologous to:** Cowper's gland / Bulbourethral gland
- **Clinical Q:**
 - ✓ Most common cyst of vulva = **Bartholin cyst**
 - ✓ Treatment = *Marsupialization* (drainage procedure)

7. Skene's Glands (Paraurethral glands)

- 2 glands → located near urethral opening
- **Function:** Secrete whitish fluid during intercourse
- **Homologous to:** Prostate gland
- **Clinical importance:** Can get infected → urethral diverticulum

High-Yield Exam Pearls

- Short female urethra = predisposes to **UTI (*E. coli*)**
- **Most sensitive part of female genitalia = Clitoris**
- **Homologues:**
 - ✓ Clitoris ↔ Glans penis
 - ✓ Labia majora ↔ Scrotum
 - ✓ Labia minora ↔ Penile urethra
 - ✓ Bartholin gland ↔ Cowper's gland
 - ✓ Skene's gland ↔ Prostate
- **Episiotomy (2nd degree)** → most common obstetric procedure in India
- **PAP Smear** = Screening test for cervical cancer

Internal Genitalia

1. Vagina

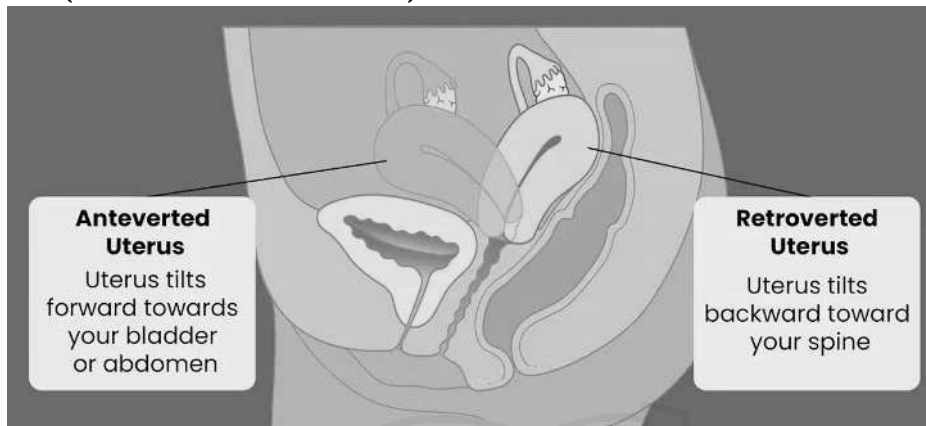
Feature	Details
Definition	Fibro-muscular canal → connects uterus & vulva
Functions	Coitus, Menstrual flow, Childbirth
Length	Ant = 7.5 cm, Post = 9 cm
Epithelium	Non-keratinized stratified squamous
pH	Acidic (3.5–4.7 in reproductive age)
Fornices	4 (Ant = shallow, Post = deep, Rt & Lt)
Blood Supply	Vaginal artery (internal iliac)
Nerve Supply	Lower 1/3 → Pudendal nerve (pain-sensitive)
Clinical	Vaginitis (<i>Candida</i> = curdy discharge, <i>Trichomonas</i> = frothy green), Fistulas (VVF, RVF)

Quick Table

Angle	Definition	Normal Value	Abnormal
Version (Inclination)	Vagina ↔ Cervix	~90°	Retroversion
Flexion	Cervix ↔ Uterus body	~120–125°	Retroflexion
Vagina ↔ Horizontal	Vagina axis ↔ ground	75° (supine), 45° (erect)	–

Positions of Uterus

1. Normal Uterus (Anteverted + Anteфлекed)



- Body leans forward on cervix (anteflexion)
 - Cervix leans forward on vagina (anteversion)
- ### 2. Retroverted Uterus
- ✓ Cervix tilted backward on vagina (loss of anteversion)
 - ✓ Can cause prolapse, infertility
- ### 3. Retroflexed Uterus
- ✓ Body bends backward on cervix (loss of anteflexion)
 - ✓ Can cause dysmenorrhea, dyspareunia

2. Uterus

Feature	Details
Definition	Pelvic organ for fetal growth & menstruation
Development	Mullerian duct (mesoderm)
Size (non-pregnant)	7.5 × 5 × 2.5 cm
Weight	50–80 g (non-pregnant); 900–1000 g at term
Shape	Non-pregnant = Pyriform; Pregnant = Round
Parts	Cervix (2.5 cm), Isthmus (0.5 cm), Body (3–3.5 cm), Fundus (1–1.5 cm)
Epithelium	Endocervix = Columnar; Ectocervix = Squamous
Blood Supply	Uterine artery (internal iliac), Ovarian artery (aorta)
Clinical	Cervical incompetence → 2nd trimester abortion (McDonald/Shirodkar stitch), Cervical cancer → at squamo-columnar junction, Fern test → ovulation/PROM

A) Uterine Angles

- Normal uterus = Anteverted (90°) + Anteфлекed (120–125°)
- **Retroversion** → infertility, prolapse
- **Retroflexion** → dysmenorrhea, dyspareunia
- **Vagina ↔ horizontal line** = 75° supine, 45° standing
- **Pelvic inclination angle** = 55–60°

B) Pelvic Diameters

- **Obstetric conjugate** = Most important inlet diameter = 10.5–11 cm
- **Diagonal conjugate** (PV exam) ≈ 12.5 cm
Formula: Obstetric Conjugate = Diagonal Conjugate – 1.5 cm
- **True conjugate (anatomical)** = 11.5 cm
- **Pelvic cavity transverse diameter** = 12 cm
- **Pelvic outlet** = AP = 11.5 cm, Transverse = 11 cm

3. Fallopian Tubes

Feature	Details
Definition	Tubes carrying ovum → uterus
Length	10–12 cm
Epithelium	Ciliated columnar
Parts	Fimbriae, Infundibulum, Ampulla, Isthmus, Interstitial
Site of Fertilization	Ampulla
Common ectopic site	Ampulla
Blood Supply	Uterine + Ovarian arteries
Clinical	Salpingitis → infertility, Tubectomy → isthmus ligation, Ectopic pregnancy → ampulla

Parts of Fallopian Tube

Part	Length	Shape / Location	Key Features	Clinical Importance
Fimbriae	~1 cm	Finger-like projections at ovarian end	Longest fimbria = Fimbria ovarica (attached to ovary)	Helps capture ovum after ovulation
Infundibulum	~2 cm	Funnel-shaped, just beyond fimbriae	Wide opening (abdominal ostium)	Site of infections (salpingitis spread)
Ampulla	~5 cm (longest part)	Thin-walled, widest lumen	Rich in ciliated epithelium	Site of fertilization, MC site of ectopic pregnancy
Isthmus	~2.5 cm	Narrow, thick muscular wall	Joins uterus at uterine cornu	Site of tubectomy (ligation)
Interstitial / Intramural	~1 cm	Part passing through uterine wall	Surrounded by myometrium	Rupture here in ectopic → severe hemorrhage

4. Ovaries

Feature	Details
Definition	Female gonads → produce ova + hormones
Size	3 × 2 × 1 cm
Weight	5–8 g
Location	Ovarian fossa of pelvis
Covering	Germinal cuboidal epithelium
Parts	Cortex (follicles), Medulla (vessels)
Hormones	Estrogen, Progesterone, Inhibin, Relaxin
Blood Supply	Ovarian artery (aorta); Veins → Rt = IVC, Lt = Renal vein
Clinical	PCOS, Ovarian torsion, Most fatal cancer = Ovarian

Ovarian Ligaments

Ligament	Attachment	Content / Function	Clinical Importance
Ovarian Ligament (Utero-ovarian ligament)	Ovary → Uterus (near cornu)	Holds ovary close to uterus; remnant of gubernaculum	Supports ovary; stretched in pregnancy
Suspensory Ligament of Ovary (Infundibulopelvic ligament)	Ovary → Lateral pelvic wall	Contains ovarian vessels, lymphatics, nerves	Clamped in oophorectomy
Mesovarium (part of broad ligament)	Hilum of ovary → Broad ligament	Carries vessels, lymphatics, nerves to ovary	Pathway for spread of ovarian tumors
Broad Ligament	Double fold of peritoneum → Uterus, fallopian tube, ovary to lateral pelvic wall	Supports uterus, tubes, ovaries; contains ligaments & vessels	Site of broad ligament fibroid
Round Ligament of Ovary (not to confuse with uterine round ligament)	Uterus (cornu) → Labia majora via inguinal canal	Maintains anteverted position of uterus	Stretching → pain in pregnancy (“round ligament pain”)

5. CERVIX

Feature	Normal	Pregnancy	Pathology
Length	~2.5 cm	Softens & shortens	Incompetence (premature opening)
Consistency	Firm (tip of nose)	Soft (lips) → Goodell’s sign	Hard/indurated (cancer)
Color	Pink	Bluish → Chadwick’s sign	Erosion/ulcer (cancer)
Mucus	Estrogen: thin, fern test (+) Progesterone: thick plug	Thick plug seals cervix	Purulent (infection), bloody (cancer)
Os	Round (nullipara), slit (multipara)	Closed till labor, dilates at term	Opens early (incompetence)
Epithelium	Ectocervix = Squamous Endocervix = Columnar	Same	SCJ → Cancer site
Clinical	Cycle changes	Goodell’s, Chadwick’s signs, mucus plug	Painless postcoital bleeding = Cervical cancer

Clinical Notes

- **Cervical incompetence:**
 - ✓ Failure of internal os closure → 2nd-trimester abortions
 - ✓ Rx = *Cervical cerclage (McDonald, Shirodkar)*
- **Cervical cancer:**
 - ✓ Most common gynecological cancer in India (after breast)
 - ✓ HPV 16 & 18 → high risk
 - ✓ Screening = PAP smear (start at 21 yrs)
 - ✓ Vaccine available (Gardasil, Cervarix)

- **Painless postcoital bleeding = Cervical cancer hallmark**
- **Cervical stenosis:** Post-surgery/scarring → infertility
 - ✓ Normal cervix feels like tip of nose (non-pregnant)
 - ✓ Pregnant cervix → soft like lips
 - ✓ Fern test positive = Estrogen effect
 - ✓ Cervical plug in pregnancy = Progesterone
 - ✓ Commonest site of cervical cancer = Squamocolumnar junction (Transformation zone)
 - ✓ HPV infection = key risk factor for cervical cancer
 - ✓ PAP smear = screening, Biopsy = confirmatory
 - ✓ Cervical incompetence → 2nd trimester abortion
 - ✓ Cervical cerclage = placed at 12–14 weeks, removed at 36–37 weeks
 - ✓ Goodell's sign = Cervical softening in pregnancy
 - ✓ Chadwick's sign = Bluish discoloration of cervix
 - ✓ Painless post-coital bleeding = Cervical cancer
 - ✓ McDonald's stitch = Cervical cerclage
 - ✓ HPV vaccine → Prevents cervical cancer

Female Breasts

1. Anatomy

Feature	Details
Location	2nd to 6th rib, sternum → mid-axillary line
Shape	Hemispherical, modified sweat gland
Extent	Axillary tail of Spence (→ axilla)
Tissue	Glandular (15–20 lobes), Fibrous (Cooper's ligaments), Fatty tissue
Nipple	Surrounded by areola; contains Montgomery's glands
Blood Supply	Internal thoracic, lateral thoracic, intercostal arteries
Nerve Supply	4th–6th intercostal nerves
Lymph Drainage	Axillary nodes (MC), internal mammary nodes

2. Physiology

Hormone	Effect on Breast
Estrogen	Ductal growth (puberty)
Progesterone	Lobulo-alveolar development (pregnancy)
Prolactin	Milk secretion (lactogenesis)
Oxytocin	Milk ejection (let-down reflex)
hPL	Synergistic with progesterone → breast development

4. Signs in Pregnancy

Sign	Description
Montgomery's tubercles	Hypertrophy of areolar glands
Areola	Dark pigmentation
Breast size	Increases due to estrogen + progesterone
Colostrum	Yellowish secretion, rich in IgA, before milk production

Exam Buzzwords

- MC cancer in women = Breast cancer
- MC site = Upper outer quadrant
- Best screening test = Mammography

- Confirmatory test = Biopsy
- Colostrum = IgA-rich, secreted late pregnancy
- Estrogen = ductal growth, Progesterone = alveolar growth
- Prolactin = milk secretion, Oxytocin = milk ejection

Breast Self-Examination (BSE)

Purpose

- Early detection of breast cancer (MC cancer in women).
- Cheap, easy, no equipment needed.

Timing

- Best time = 7–10 days after onset of menstruation (when breasts are least tender).
- Post-menopausal / pregnant women → choose a fixed day every month.

Steps of BSE

Step	How to Perform	What to Look For
1. Inspection	Stand before mirror, arms: a) at sides b) raised overhead c) hands on hips	Look for: asymmetry, dimpling, peau d'orange, nipple retraction, discharge, skin changes
2. Palpation (Standing/ Sitting)	Use finger pads of 3 middle fingers; check both breasts in circular / wedge / vertical strip method	Lumps, thickening, tenderness
3. Palpation (Lying Down)	Place pillow under shoulder, arm behind head, palpate opposite breast	Same as above
4. Axilla & Clavicle	Palpate axillary and supraclavicular areas	Enlarged lymph nodes

Findings Requiring Medical Attention

- New lump
- Nipple discharge (esp. bloody)
- Retraction or inversion of nipple
- Skin dimpling or redness
- Persistent pain or swelling

NORCET Buzzwords

- Best time = 7–10 days after menstruation
- Post-menopausal = fixed day each month
- MC site of cancer = Upper outer quadrant
- Confirmatory test for cancer = Biopsy
- Most important prognostic factor = Axillary lymph nodes

Miscellaneous

Table

Organ	Type (External / Internal)	Key Anatomy	Functions	Homologous in Male	Clinical Points
Mons Pubis	External	Hair-bearing triangular area above clitoris	Protection	–	Cosmetic importance

Clitoris	External	Erectile body, 2.5 cm	Sexual stimulation (erogenous zone)	Glans penis	Most sensitive part
Labia Majora	External	Outer folds, hairy, sebaceous glands	Protects vestibule	Scrotum	Site of sebaceous cyst
Labia Minora	External	Inner folds, no hair	Bound vestibule	Penile urethra	Meet posteriorly → fourchette
Vestibule	External	Space between labia minora	Contains urethra & vaginal openings	–	Short urethra → ↑ UTI risk
Bartholin's glands	External	2 glands below vaginal opening	Alkaline mucus in intercourse	Cowper's glands	Bartholin cyst → marsupialization
Skene's glands	External	Near urethral opening	Secrete whitish fluid	Prostate gland	Urethral diverticulum risk
Vagina	Internal	7.5–9 cm fibromuscular tube	Coitus, menstruation, delivery	–	Acidic pH (3.5–4.7); Vaginitis (Candida, Trichomonas)
Uterus	Internal	7.5 × 5 × 2.5 cm, pyriform	Menstruation, pregnancy	–	Cervical incompetence → abortion; Cervical cancer → SCJ
Cervix	Internal (part of uterus)	2.5 cm neck of uterus	Cervical mucus secretion, sperm capacitation	–	Squamocolumnar junction → cancer site; Fern test → ovulation
Fallopian Tubes	Internal	10–12 cm; parts = fimbriae, infundibulum, ampulla, isthmus	Ovum transport, fertilization (ampulla)	–	Common site ectopic (ampulla); Tubectomy (isthmus)
Ovaries	Internal	3 × 2 × 1 cm, almond-shaped	Oogenesis, hormones (E, P, Inhibin, Relaxin)	Testes	PCOS; Ovarian torsion; Most fatal cancer = ovarian

Homologous Organs – Male vs Female

Female Organ	Male Homologous Organ	Key Point
Clitoris	Glans penis	Erectile, highly sensitive
Labia Majora	Scrotum	Both from labio-scrotal folds
Labia Minora	Penile urethra (ventral)	Form vestibule boundaries
Bartholin's glands	Cowper's (Bulbourethral) glands	Secrete mucus during intercourse
Skene's glands	Prostate gland	Paraurethral glands
Ovaries	Testes	Gamete & hormone producing gonads

Round ligament of uterus	Gubernaculum (testicular ligament)	Embryological remnant
Uterus & upper vagina	Prostatic utricle	Mullerian duct derivative
Hymen	Urogenital sinus folds (no exact male equivalent)	Marks vaginal introitus
Origin	Female Organs	
Ectoderm	Clitoris, Labia majora, Labia minora, Mons pubis, External genitalia, Lower 1/3 vagina	
Mesoderm	Uterus, Fallopian tubes, Upper 2/3 vagina, Ovaries	
Endoderm	Bartholin's glands, Skene's glands, Hymen, Bladder, Urethra	

High-Yield Exam Pearls

- **Müllerian duct anomaly** → congenital uterine malformations (bicornuate, septate, etc.)
- **Vaginal development** = Dual Origin (upper 2/3 mesoderm, lower 1/3 ectoderm)
- **Most common site of cancer in females** → Breast (but gynecology: Cervix, Ovaries)

Ovarian Cycle vs Uterine Cycle vs Hormones

Phase	Ovarian Cycle	Uterine Cycle	Dominant Hormone	Key Events
Day 1–5	Early Follicular Phase	Menstrual Phase	↓ Estrogen, ↓ Progesterone	Shedding of endometrium (menses)
Day 6–14	Late Follicular Phase	Proliferative Phase	Estrogen ↑ (from developing follicles)	Follicle growth (FSH), Endometrium thickens, Cervical mucus watery (Fern test +)
Day 14	Ovulation	Transition	LH Surge (triggered by Estrogen peak)	Ovum released from Graafian follicle (at Ampulla of tube)
Day 15–28	Luteal Phase	Secretory Phase	Progesterone ↑ (from corpus luteum)	Endometrium coiled, vascular; receptive to implantation
If No Pregnancy	Corpus luteum regresses → corpus albicans	Premenstrual Phase → Menstruation	Hormones ↓	Endometrial shedding starts again
If Pregnancy	Corpus luteum maintained by hCG	Endometrium maintained (decidua)	Progesterone + hCG	Implantation, Pregnancy sustained

Hormones In Pregnancy

Major Hormones & Functions

1. Human Chorionic Gonadotropin (hCG)

- Source: Syncytiotrophoblast (placenta)
- Detectable: 8–9 days after fertilization (basis of pregnancy test)
- Function: Maintains Corpus Luteum (→ Progesterone secretion till placenta takes over at ~12 wks)
- Clinical: ↑ in Molar pregnancy, Choriocarcinoma, Multiple pregnancy

↓ in Ectopic pregnancy, Missed abortion

2. Progesterone

- **Source:** Corpus luteum (1st trimester), then Placenta
- **Function:**
 - ✓ Maintains endometrium (decidua)
 - ✓ Relaxes smooth muscles → prevents uterine contractions (preterm labor prevention)
 - ✓ Thickens cervical mucus plug
 - ✓ Prepares breast for lactation (lobulo-alveolar development)
- **Clinical:** Deficiency → abortion risk

3. Estrogen

- **Source:** Placenta (syncytiotrophoblast)
- **Types:**
 - ✓ Estriol (E3): Pregnancy-specific
 - ✓ Estradiol (E2), Estrone (E1)
- **Function:**
 - ✓ Uterine growth, blood supply ↑
 - ✓ Breast duct growth
 - ✓ Softening of cervix
- **Clinical:** Estriol used as marker for fetal well-being

4. Human Placental Lactogen (hPL / hCS)

- **Source:** Placenta
- **Function:**
 - ✓ Anti-insulin → causes gestational diabetogenic state
 - ✓ Mobilizes free fatty acids for mother → saves glucose for fetus
 - ✓ Prepares breast for lactation
- **Clinical:** ↑ → multiple pregnancy; ↓ → placental insufficiency

5. Relaxin

- **Source:** Corpus luteum & Placenta
- **Function:**
 - ✓ Relaxes pelvic ligaments & cervix
 - ✓ Softens pubic symphysis → facilitates delivery

6. Prolactin

- **Source:** Maternal pituitary
- **Function:** Milk synthesis post-delivery
- Inhibited by estrogen & progesterone during pregnancy (so milk starts only after delivery)

7. Oxytocin

- **Source:** Posterior pituitary (maternal + fetal)
- **Function:**
 - ✓ Stimulates uterine contractions during labor
 - ✓ Ejection of milk (let-down reflex)
- **Clinical:** Given as drug to induce labor, control PPH

8. Cortisol & Thyroid Hormones

- **Cortisol:** ↑ in pregnancy (maternal hypercortisolism)
- **Thyroid:** ↑ TBG → ↑ Total T3 & T4; Free T3/T4 = Normal

Quick Table for Revision

Hormone	Source	Function / Role	Clinical Point
hCG	Placenta (syncytiotrophoblast)	Maintains corpus luteum	Pregnancy test, trophoblastic tumors
Progesterone	CL → Placenta	Maintains pregnancy, relaxes uterus	Deficiency → abortion
Estrogen	Placenta	Uterine & breast growth	Estriol marker for fetal well-being
hPL	Placenta	Anti-insulin, fetal nutrition	Gestational diabetes
Relaxin	Placenta, CL	Relaxes pelvis & cervix	Labor facilitation
Prolactin	Pituitary	Milk synthesis	Lactation starts after delivery
Oxytocin	Posterior pituitary	Uterine contraction, milk ejection	Induce labor, PPH control

High-Yield Exam Tips (NORCET MCQs):

- First hormone detected in pregnancy = hCG
- Hormone causing gestational diabetes = hPL
- Hormone maintaining pregnancy = Progesterone
- Fetal well-being marker = Estriol (E3)
- Milk ejection hormone = Oxytocin

1. Progesterone – Functions Mnemonic “PREGNANCY”

- P – Prevents uterine contraction (uterine relaxant)
- R – Regulates endometrium (decidualization, implantation)
- E – Enhances breast lobulo-alveolar growth
- G – Gingivitis (gum changes)
- N – Nervous system growth (neuroprotective)
- A – Antagonizes estrogen sometimes
- N – Normalizes risk of endometrial cancer (protective)
- C – Contraceptive role (OCP)
- Y – Yields immunosuppression (↓ fetal rejection)

2. Serum Progesterone Levels Table

Stage / Condition	Normal Progesterone Level
Male	0.3 ng/ml
Female (non-pregnant)	0.9 ng/ml
Pre-Ovulation	> 2 ng/ml
Post-Ovulation	> 5 ng/ml
Post-Menopause	< 1 ng/ml
1st Trimester Pregnancy	10 – 90 ng/ml
Peak (Day 21 cycle)	> 10 ng/ml

3. Corpus Luteum vs Placenta (Source of Progesterone)

Feature	Corpus Luteum	Placenta
Time Active	0 – 7/9 weeks	After 7–9 weeks till term
Hormone Maintained By	LH	hCG
Main Function	Early pregnancy maintenance	Sustains pregnancy till term
Clinical Importance	If fails → abortion risk	If fails → fetal demise

4. Progesterone vs Estrogen (Comparison)

Feature	Progesterone (P4)	Estrogen (E2)
Nickname	Hormone of Pregnancy	Hormone of Femininity
Effect on Endometrium	Thickens (decidua, implantation)	Proliferation (growth)
Effect on Uterus	Relaxes (anti-contraction)	Increases excitability
Effect on Breast	Lobulo-alveolar growth	Ductal growth
Effect on Temp	↑ basal body temp	No effect
Contraceptive Role	Used in OCP, emergency pill	Not alone

5. Placental Hormones Mnemonic

“PEP H”

- P – Progesterone
- E – Estrogen
- P – PAPP-A (Pregnancy Associated Plasma Protein A)
- H – HPL / HCS (Human Placental Lactogen / Somatomammotropin)
(+ β -hCG is also secreted)

Physiology of Progesterone (Flow Chart Theory)

1. Source / Production

- Cholesterol → Pregnenolone → Progesterone

➤ Produced by:

- ✓ Corpus luteum (early pregnancy)
- ✓ Placenta (after 7–9 weeks → till term)
- ✓ Adrenal cortex
- ✓ Testes

2. Secretion Pattern

- ✓ Follicular phase → Low level
- ✓ Luteal phase (post-ovulation) → High level
- ✓ Pregnancy → Markedly increased (maintains uterus)
- ✓ Menopause → Low / absent

3. Actions on Body Systems

A. On Endometrium

- Converts proliferative phase → secretory phase
- Thickens endometrium (decidualization)
- Prepares for implantation

B. On Uterus

- Uterine relaxant
- ↓ Myometrial contractions → prevents preterm labor

C. On Breast

- Stimulates lobulo-alveolar development
- Prepares breast for lactation

D. On Temperature

- ↑ Basal body temperature by 0.2–0.5°C (after ovulation)

E. On CNS

- Neuroprotective, mood-modulating effect
- Used in OCPs (contraceptive action)

F. On Immune System (Pregnancy)

- ↓ Maternal immune response (prevents fetal rejection)
- Pregnancy = state of immunosuppression

4. Clinical Notes

- Maintains pregnancy → “Hormone of Pregnancy”
- ↓ Progesterone → Abortion / Preterm labor risk
- **Used in:**
 - ✓ OCPs (Oral Contraceptive Pills)
 - ✓ Luteal support in infertility treatment
 - ✓ Prevention of preterm labor

Flow Pattern (Summary):

Cholesterol → Progesterone → Acts on (Endometrium, Uterus, Breast, CNS, Temperature, Immunity) → Maintains Pregnancy

2. Estrogen

Basic

- Precursor: Cholesterol (Steroid Hormone)
- N Serum Cholesterol: 150–199 mg/dl
- 230 mg/dl → Cardiac risk

Types of Estrogen

1. Estradiol (E2 / 17-β Estradiol) → Main, active, reproductive age
2. Estrone (E1) → After menopause
3. Estriol (E3) → Pregnancy
4. Estetrol (E4) → Only pregnancy

Important for Skin, Bones, Blood vessels

- Collagen type I (skin, bone)
- Collagen type IV (lens)

Sources

- Ovary (Graafian follicle, CL)
- Placenta
- Adrenal cortex
- Testes (males)

Blood Levels

- Female: 35–500 pg/ml
- Pre-ovulation: 200–500 pg/ml
- Male: ~50 pg/ml

Functions of Estrogen

Mnemonic: Feminine Power

1. F – Female secondary sexual characters
2. E – Endometrium proliferation (Proliferative phase)
3. M – Maintains bone → ↓ resorption
 - ✓ After menopause ↓ → Osteoporosis (silent thief of bone)
4. I – Improves lipid profile → ↑ HDL, ↓ LDL → ↓ Atherosclerosis, ↓ BP
5. N – Neuromuscular → Collagen synthesis, flexible tendons, risk of muscle injury
6. I – Immuno-modulation → mild anti-inflammatory
7. N – Nutrition & Fat → Breast, thigh, buttock deposition; less on abdomen
8. E – Enlarges uterus, vaginal lubrication

Extra Physiological Effects

- ↓ Bowel movement → Constipation (pregnancy)
- ↓ Melanin (skin changes)

- ↑ Na⁺, fluid retention → Hypervolemia + Physiological Hypotension
- ↑ Alveolar function → Respiratory alkalosis in pregnancy (↑ pH, ↓ CO₂)
- Stimulates LH release (ovulation)
- ↑ Sexual behavior/desire
- ↑ Clotting factors II, VII, IX, X → Risk of thrombosis
- ↓ Appetite → Anorexia in pregnancy (via serotonin suppression)
- Parturition (labor initiation via oxytocin release)
- Excretion: 60% urine, 20% stool

Estrogen & Parturition (Delivery)

- Hypothalamus → APG → ACTH → Adrenal Cortex
- ↑ Estrogen, Cortisol, Progesterone
- Estrogen crosses placenta → Maternal hypothalamus → ↑ Oxytocin → Uterine contraction → Delivery

Rapid Flow (Summary)

Cholesterol → Estrogen (E1, E2, E3, E4)

↓

Sources: Ovary, Placenta, CL, Adrenal, Testes

↓

Actions:

- Secondary sexual characters
- Endometrium proliferation
- Bone health (↓ osteoporosis)
- CVS: ↑ HDL, ↓ LDL, vasodilation
- Uterus: Growth, lubrication, labor initiation
- Breast: Fat deposition
- Pregnancy: Hypervolemia + Respiratory alkalosis
- ↑ LH, oxytocin, clotting factors

↓

Outcome: Fertility, Pregnancy support, Parturition

3. RELAXIN

Mnemonic: RELAX

- **R** – Relaxes **symphysis pubis & pelvic ligaments** → helps in **delivery**
- **E** – Enhances **endometrial growth** → supports implantation & pregnancy
- **L** – Leads to **sperm migration** → improves fertility
- **A** – Activates **Nitric Oxide (NO)** → vasodilation → improves **cardiac output**
- **X** – X-tra role in **softening cervix** (for labor)

Clinical Significance

- Peaks in **pregnancy** → prepares pelvis & uterus for labor
- Supports **hemodynamic changes** (vasodilation, ↓ vascular resistance)
- Helps in **fertility** by aiding sperm motility

Rapid Flow Summary

Corpus Luteum / Placenta → Relaxin → (1) Relax symphysis pubis → Delivery, (2) Sperm migration → Fertility, (3) ↑ NO → Vasodilation & Cardiac function, (4) Endometrial growth → Pregnancy support

LH & FSH – Gonadotropins

Origin

- Both are glycoprotein hormones
- Secreted by Anterior Pituitary (APG – basophil cells)
- Under control of GnRH (Hypothalamus)

1. Follicle Stimulating Hormone (FSH)

In Females

- Stimulates growth & maturation of ovarian follicles
- ↑ Estrogen secretion (via granulosa cells)
- Helps in ovulation (works with LH)
- Maintains follicular phase of menstrual cycle

In Males

- Acts on Sertoli cells → promotes spermatogenesis
- Stimulates production of ABP (Androgen-binding protein)

2. Luteinizing Hormone (LH)

In Females

- LH Surge → Causes ovulation (Day 14 of cycle)
- Maintains Corpus Luteum → Secretes Progesterone
- Promotes Theca cells → Androgen production

In Males

- Acts on Leydig cells → Testosterone secretion
- Called ICSH (Interstitial Cell Stimulating Hormone)

Blood Level & Regulation

- Controlled by GnRH (pulsatile)
- **Negative feedback:**
 - ✓ Estrogen, Progesterone, Testosterone inhibit LH/FSH
 - ✓ Inhibin (from Sertoli/Granulosa cells) inhibits FSH

Flowchart (Summary)

Hypothalamus → GnRH → Anterior Pituitary → LH & FSH

In Females

- FSH → Follicle growth → Granulosa cells → Estrogen ↑
- LH → LH Surge → Ovulation → Corpus luteum → Progesterone ↑

In Males

- FSH → Sertoli cells → Spermatogenesis
- LH → Leydig cells → Testosterone ↑

MCQ High-Yield Points

- LH Surge → Ovulation
- FSH → Granulosa cells, LH → Theca cells
- Inhibin → Selectively inhibits FSH
- ICSH = LH in males

LH & FSH – Flowchart (Theory Style)

Step 1: Hypothalamus

↓ (secretes GnRH in pulsatile manner)

Step 2: Anterior Pituitary (APG – Basophils)

↓ (secretes Gonadotropins → LH & FSH)

In FEMALES

FSH Pathway

- **FSH → Acts on Granulosa cells**
 - ↓
- **Stimulates follicle growth & maturation**
 - ↓

- ↑ Estrogen secretion
- ↓
- Estrogen → Endometrial proliferation (proliferative phase)

LH Pathway

- LH → LH Surge (Day 14)
- ↓
- ovulation
- ↓
- Maintains Corpus Luteum
- ↓
- Corpus luteum secretes Progesterone
- ↓
- Progesterone → Endometrium secretory phase (implantation, pregnancy maintenance)

In MALES

FSH Pathway

- FSH → Acts on Sertoli cells
- ↓
- Stimulates Spermatogenesis
- ↓
- Produces ABP (Androgen Binding Protein) → concentrates Testosterone in seminiferous tubules

LH Pathway

- LH (a.k.a. ICSH) → Acts on Leydig cells
- ↓
- ↑ Testosterone secretion
- ↓
- Testosterone → Male secondary sexual characters, libido, spermatogenesis support

Regulation

- **Negative feedback:**
 - ✓ Estrogen, Progesterone, Testosterone → inhibit LH & FSH
 - ✓ Inhibin (from Sertoli / Granulosa cells) → selectively inhibits FSH

Exam High-Yield Lines

- LH Surge → Ovulation
- FSH → Follicle & Granulosa (female), Sertoli (male)
- LH → Theca cells (female), Leydig cells (male)
- Inhibin inhibits FSH (NOT LH)
 - ✓ Progesterone → Hormone of Pregnancy
 - ✓ Estrogen → Hormone of Femininity (bones, CVS, skin, sexual behavior)
 - ✓ Relaxin → Delivery hormone (relaxes pelvis, aids sperm, vasodilator)
 - ✓ Inhibin → selectively inhibits FSH

LH & FSH (Gonadotropins)

Hormone	Female Role	Male Role	MCQ High Yield
FSH	Follicle growth, Granulosa cells → ↑ Estrogen	Sertoli cells → Spermatogenesis, ABP	Inhibin inhibits FSH
LH	LH Surge → Ovulation; Maintains CL → Progesterone + Relaxin	Leydig cells → Testosterone (ICSH)	LH Surge = Ovulation