Toppersnotes
Unleash the topper in you

NEET-PG

PART-B

VOLUME-II

Pathology

SIERRA INNOVATIONS
Private Limited

PATHOLOGY

G.I.T.

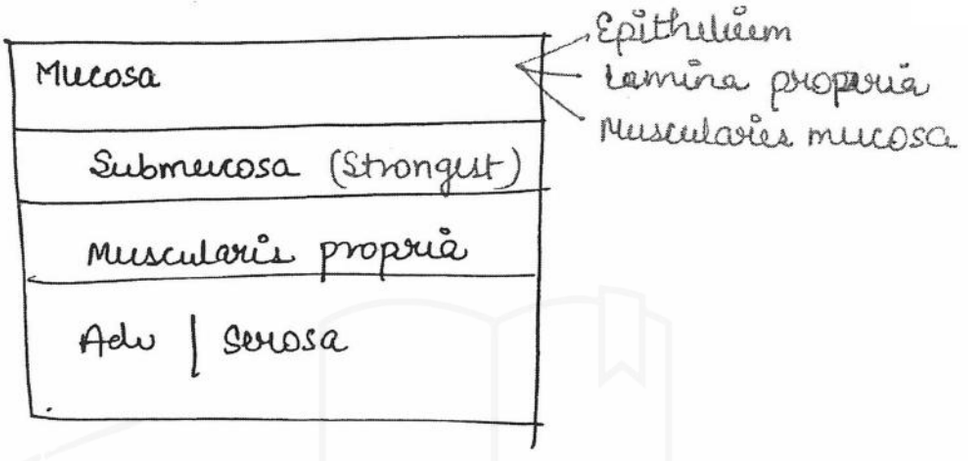

Esophageal Trauma

Mallory Weiss tear

↓

Forced vomiting

↓

against

delayed relaxation of Cardia (Stomach)

↓

only mucosal tear

- MC site = Cardia of stomach > Esophagus

Boerhaav trauma

↓

Forceful vomiting

↓

against closed glottis

↓

all 4-layers teared.

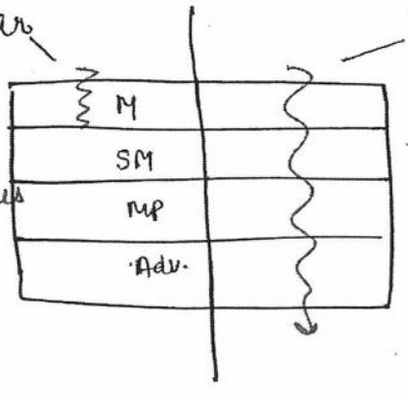

Lower $\frac{1}{3}$rd of esophagus

↓

(lt) posteriolateral side

cat ← **Feline Esophagus** :

- MC a/w GERD <<< E°-Esophagitis → RQ
  (Allergic ")

>15 eosinophil / HPF
↓
Confirmed the dx.

- Endoscopy ;

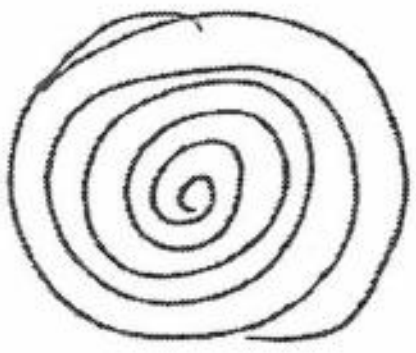

- double contrast Esophagogram :

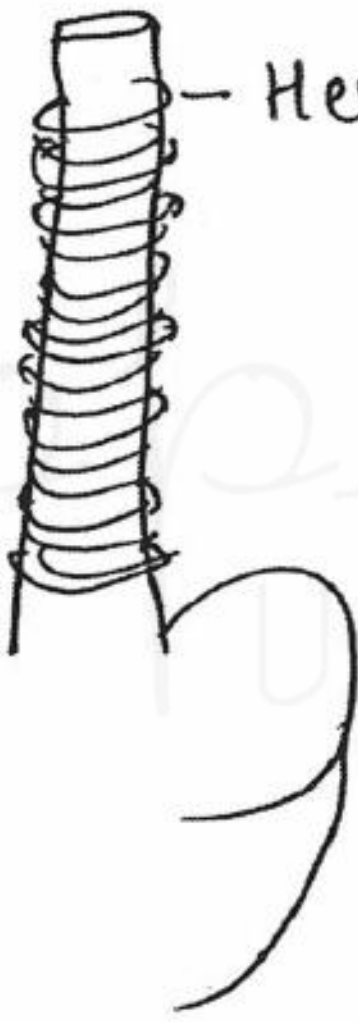

↓
Trachealization of esophagus.

MC Esophageal tumor

Benign tumor
↓
leiomyoma

Malignant tumor

India } Squamous cell Ca >> Adeno Ca
World }
↓
MC - site
↓
Middle $\frac{1}{3}$rd of esophagus

MC paraneoplastic synd
for esophagus - ↑↑Ca^{+2}

Stomach

Gastritis

Inflammation ⊕ ↑↑↑

Gastropathies

- Hyperplasia & Hypertrophy
  +
  Inflammation absent or minimal.

eg: **Menetriere's disease**;

↑ TGFα
↓
↑ Hyperplasia
↓
of Rugal folds (cerebriform) → loss of protein
↓
"protein losing gastropathy"

- Risk factor for - Carcinoma Transform
- Bx:
  - Foveolar cell Hyperplasia + No/scanty inflammation.

Gastritis

Acute

- Neutrophilic infiltration
- No mucosal atrophy.
- **Causes**:
  - NSAIDs
  - Stress

Chronic

- Lymphocytic infiltration.
  ↓
  Mucosal Atrophy.

Cause:

- Autoimmunity
- H. pylori - (MC)

↓

Stress ulcer

Cushing ulcer → due to Head Injury

- MC-site = Stomach (cardia)

Curling ulcer → Burns.

Q Proximal duodenum

Autoimmune (Type-A)

- Autoimmune diseases
- MC site: Body > Fundus

H. Pylori induced (Type-B)

- MC H. pylori (N)(+) in Antrum of stomach

Q ① Urease → Buffer the acid → NH_3

② Cag-A gene: Cytotoxic

③ Bab-A = Adhesions → MC in 'O'-B.gp → ↑ Risk of ulcers

- MC-site = Q Antrum → also for Cancer d/t H. pylori.

Bx; H. Pylori



H. pylori → IOC

- Non-invasive: ELISA (serology)
- Invasive → Rapid urease breath test

Gold Std: Bx + special stain

Silver: Warthin Starry → Yellow → Spiral

Non-silver: Giemsa stain

Peptic Ulcer disease

Gastric ulcer

1. MC - site = Antrum
   ↓
   lesser curvature
2. Pain = Relieved by vomiting
3. Malignant transformation ↑↑

duodenal ulcer - MC

- Proximal duodenum (C in 2.5 cm)
- Pain - Relieved by food intake.
- ⊖

- MC complication of Peptic ulcer = Bleeding
- MCC of death in peptic ulcers = Perforation

STOMACH CA

↓

MC

Benign

↓

Adenoma

Malignant

↓

1. MC - Epithelial tumor
   ↓
   - Gastric adenoCa.
2. NHL (Maltoma)
3. GIST (Gastro intestinal stromal tumor)
   ↓
   - MC - site - Stomach > SI
   - MC - Mesenchymal tumor = GIST

Etiology of GIST : also

- NF-1
- Carney's triad
  - Non-hereditary GIST
    - Paraganglioma (PG)
    - Pulmonary chondroma / Hamartoma
- Carney-Stratakis syndrome
  - Hereditary
  - Mutation in SDH – B/C/D (Succinate dehydrogenase)
  - GIST + PG

- **Pediatric-GIST :**
  - a/w SDH – B mutat^{n}.
  - No → CKIT mutat^{n}
  - NO → PDGFR-α gene mutation.

- **Adult GIST**
  - CKIT gene (80%)
  - PDGFR-α-gene (15-20%)
  - → Monoclonal Ab
  - At 13/14/17
  - → DOG-1 ← Most special, Best IHC
  - → For metastatic GIST
  - → Best also.

- **Malignant GIST ; Dx ;**
  - ↓
  - > 10 Mitotic figures / HPF
  - > 5 cm size
  - & Lobulated contour & Necrosis
  - Liver metastasis / peritoneal metastasis

Malabsorption Syndrome

MC sign = Steatorrhoea

↑ Fecal Fat

Bulky and Malodour

Infective

(1) Tropical sprue;

- E. coli infection

MC site = Ileum. (Megaloblastic Anaemia)

Bx; Nondiagnostic

- PCR - Confirm the Dx

(2) Whipple's disease:

- MC- site - Small Intestine
- Tropheryma whippelii (Gr +ve)

Bx: Dx

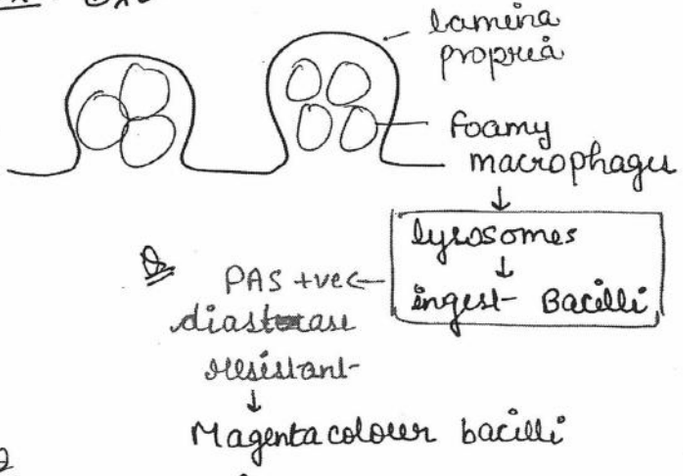

(3) Entamoeba Histolytica:

- MC- site - Caecum
- Bx; Dx



Non- infective

(1) Celiac disease

- Gluten sensitive enteropathy
- Immune mediated malabsorption syndrome
- Gluten = Gliadin protein

cereals

B = Barley
R = Rye
O = Oat
W = Wheat

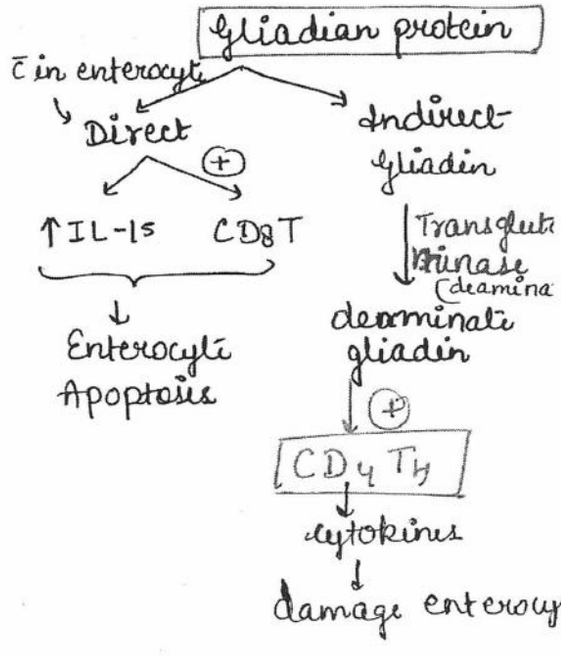

1. Macrophage like organism.
2. Central prominant Nucleoli
3. Erythrophagocytosis.

(4) Giardiasis:

- MC parasitic infection causing malabsorption
- MC-site = Small intestine

Pear shaped

Bx:



Pear shape (front view)

comma shaped / Sickle " (Side view)

- Immunodeficient person.
- Recurrent diarrhoea d/t Giardia
  ↓
  (Common Variable of Immunodeficient disorder)

Dx: (Bx is not diagnostic)

↓

Multi-modality approach

(A) serology
- most sensitive
- ↓
- Ig A Ab against Transglutaminase
- ↓
- most specific
- ↓
- Anti-endomysial antibody

(B) HLo Gluten diet
- ↓
- diarrhoea (+)

No gluten diet
- ↓
- No diarrh.

(C) Bx
- ↓
- MC-site
- ↓
- Proximal duodenum (Iron deficiency)



mucosa
- ↓
- Thickness will remain same. (N)

villi Atrophy.

crypt
- ↓
- crypt Hyperplasia

cryptitis, crypt abscess } Absent.

☆ In GIT - MC = Enteropathy associated T-cell lymphoma.
in coeliac ds.

Inflammatory Bowel ds

- Hygiene Hypothesis
  ↓
  Refrigrator ⇒ Bact. ↓↓
  food
  ↓
  ↓ Mucosal immunity (gut)

- Intermittent Mucosal & Bloody diarrhoea.

Crohn's disease

- MC site = Ileum
- Rectum = spared
- a/w { HLA - DR-1
  CD4 T_{H1}
  ↓
  Granuloma (+)
- Earliest manifestation (GIT) of IBD = Aphthous ulcer

Ulcerative colitis

- Rectosigmoid colon - MC site
- DR_2
- CD4 T_{H2}
  ↓
- Mast cell & Eosinophils

Gross:

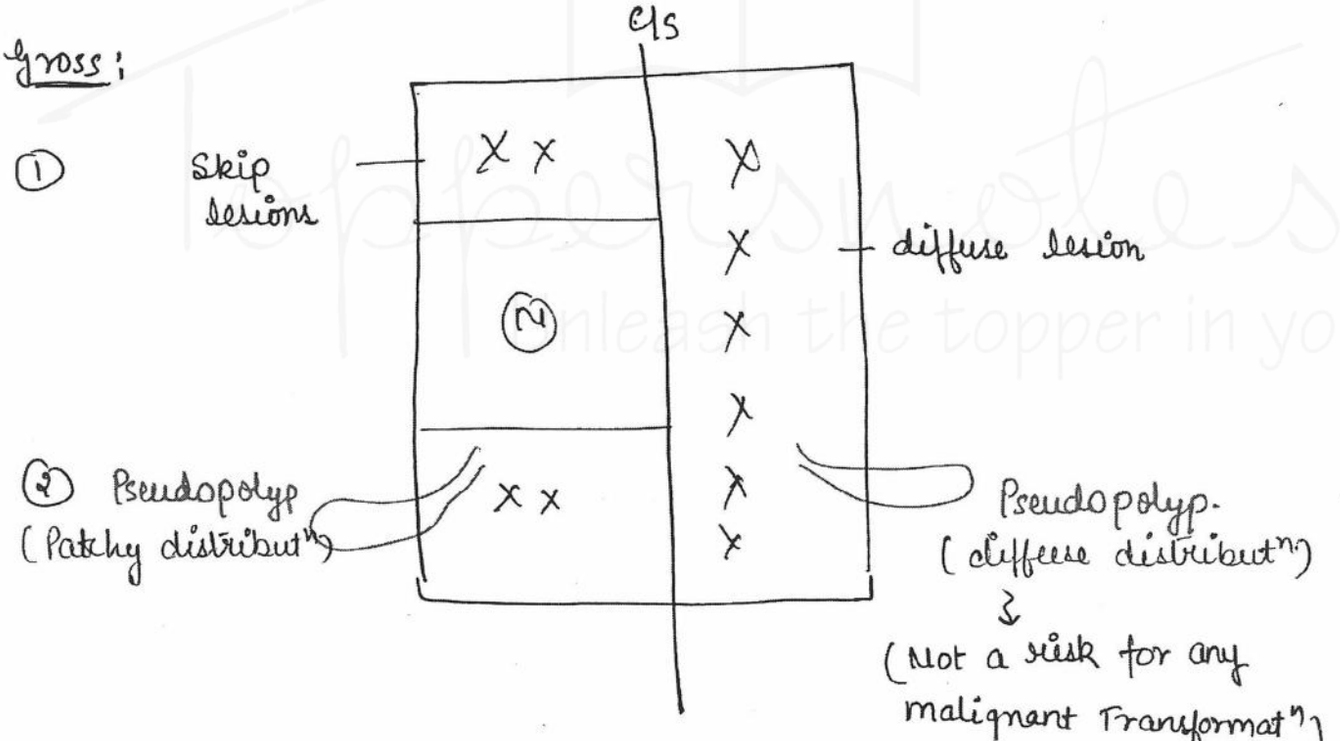

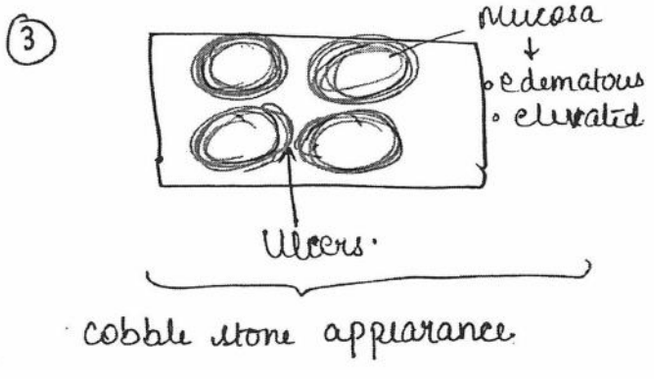

- Chronic UC (loss of haustrations)
  ↓
  Featureless colon
  ↓
  lead pipe deformity

④

Inflammation + fibrosis

Gross | Radio.

↓

"String of Kanator sign."

M | E :

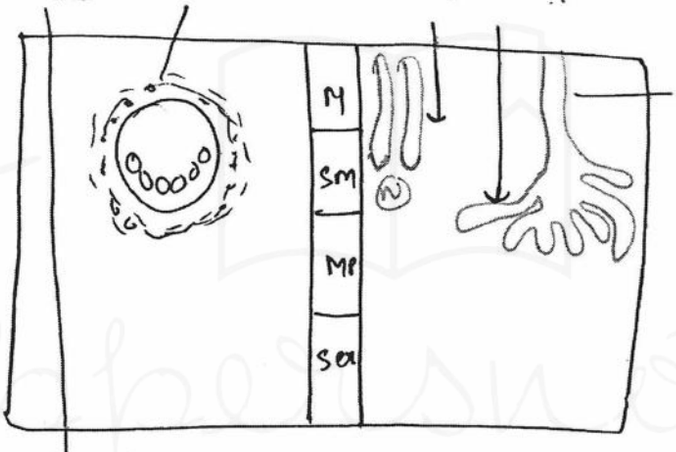

Transmural ulcer

- Perforation | Adhesion | peritonitis

← cryptitis | crypt Abscess. →

- MCC of death in IBC = Peritonitis < Malignancy

↓

Crohn's << UC

Small Intestine

MC Benign → Adenoma

MC 1° Malignancy → Adeno Ca > Carcinoid.

POLYP

Non-neoplastic

(1) Juvenile polyp:
- MC mutat^{n} = SMAD-4
- No risk = Malignacy

(2) Juvenile polyposis syndr.
- >100 polyp.
- ↑ Risk = Colon Ca

(3) Peutz-Jegher-Polyp:
- a/w LKB-1 | STK-11 gene mutation
- Hyperpigmented macules → Pigmented lesion lips | anal | perinasal area
- \+
- Gr. I. Polyp.

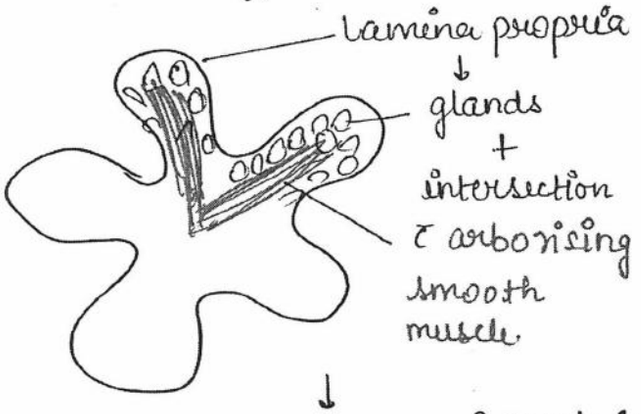

↑ Risk for → Breast Ca, Pancreas Ca & Bony, Colon Ca, Thyroid Ca

- Gross - Bosselated surface.

Neoplastic

(1) Tubular:

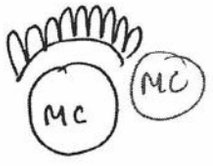

(2) Villous

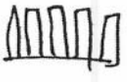

- MC - Malignancy

(3) Tubulovilli

Familial

(1) Gardener Syndrome → GI polyp, Skin polyp, Ab(N)- dentition

(2) Turcot synd.: GI-polyp. + Medulloblastoma of Brain

(5) Bannayan Rwal Caba / Cowden Syndrome

PTEN mutatn → PTEN Hamartoma polyp syndrome.

* Pseudomembranous polyp : (Ab) against cephalosporine

↓

after mocosal damage

↓

Fibrin + Infl. cells exudates comes out & deposited

↓

Valcano like eruption

• Clostridium difficili

↓

Toxin

- Staph
- Shigella
- Ischaemia

Liver

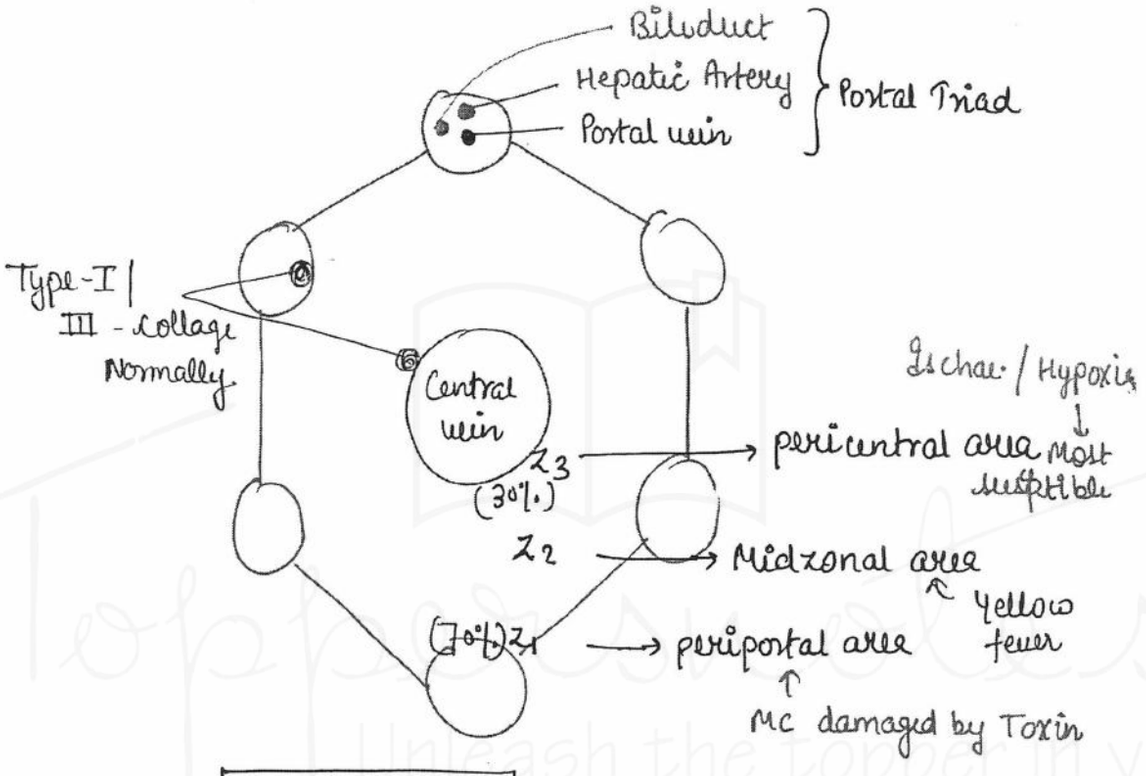

Nut Meg liver

- chronic passive congestion → More RBCs
  - → zone-3 affected more
  - Pericentral → Necrosis + [dead cells + RBC] → "Dark red area" (AIIMS)
  - periportal area → (N) | Viable → "Yellow tan area"

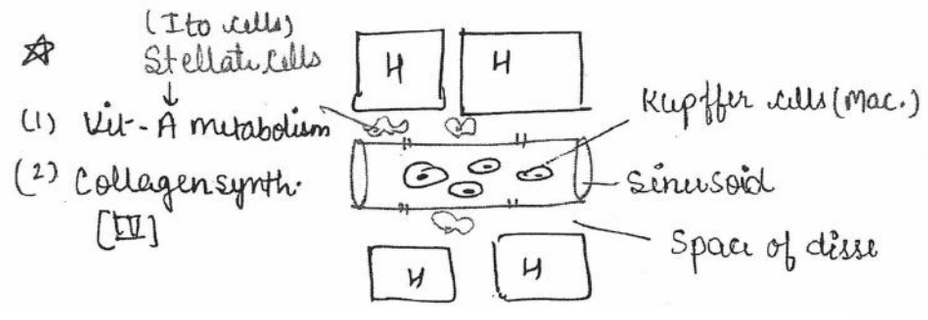

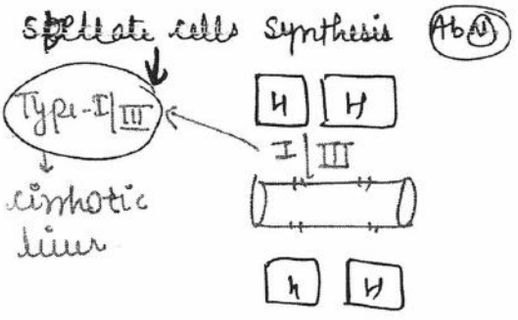

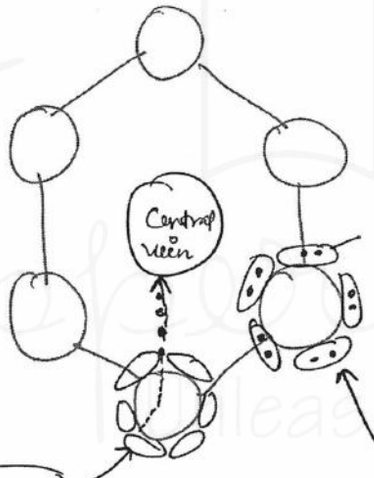

UPSC #1 14

Chronic Active Hepatitis

Limiting plate damaged

Chronic Persist Hepatitis

- Limiting plate - intact

Hepatitis

Acute Hepatitis

(1) Ballooning degeneration

(2) Apoptotic bodies | Councilman Bodies

(3) Bridging necrosis

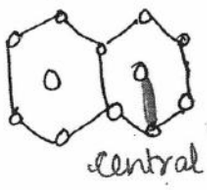

Chronic hepatitis

- ground glass hepatocytes
- Piecemeal Necrosis (limiting plate → damaging the periportal area.)
- Bridging Necrosis all type & fibrosis — (MC)

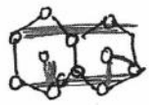

- fatty changes

liver cell damage

↓

LFT

liver Synthesis function

↓

- PT
- S. Bilirubin
- S. albumin

↓

- PT is single Best marker for LFT.

liver cell integrity

↓

- AST
- ALT → More specific for liver
- LDH
  ↓
  liver cell Ca.

Billiary excretion function

↓

- Alkaline phosphatase
- γ- glutamyl trans peptidase (GGT).
- 5'- Nucleotidase.

q/w Alcohol intake.

PT ↑

AST | ALT ↓↓↓

Recovery

- PT (N)
- ↓ AST | ALT

fulminant

- PT ↑
- AST | ALT ↓↓

AST | ALT | LDH

Alcohol liver ds

AST > ALT

Viral hepatitis

ALT > AST

Alkaline phosphatase ↑

Bile duct damage

↓

Increased

GGT
5' Nucleotidase

Bone damage

↓

(N)